

## VIDEOS IN CLINICAL MEDICINE

## Abscess Incision and Drainage

Michael T. Fitch, M.D., Ph.D., David E. Manthey, M.D.,  
Henderson D. McGinnis, M.D., Bret A. Nicks, M.D., and Manoj Pariyadath, M.D.

From the Department of Emergency Medicine, Wake Forest University School of Medicine, Winston-Salem, NC. Address reprint requests to Dr. Fitch at the Department of Emergency Medicine, Wake Forest University Health Sciences, Medical Center Blvd., Winston-Salem, NC 27157, or at [mfitch@wfubmc.edu](mailto:mfitch@wfubmc.edu).

N Engl J Med 2007;357:e20.  
Copyright © 2007 Massachusetts Medical Society.

**INDICATIONS**

Skin and soft-tissue infections, including cutaneous abscesses, are commonly encountered among patients presenting for treatment in primary care offices and emergency departments. Cutaneous abscesses can occur in any area of the body but are commonly found in the axillae, buttocks, and extremities. Incision and drainage constitute the primary therapy for the management of cutaneous abscess; antibiotic treatment alone is inadequate for treating many loculated collections of infectious material. Abscess incision and drainage are most often outpatient procedures, and most localized skin abscesses without associated cellulitis can be managed without antibiotics.<sup>1-5</sup> Issues related to skin infections that require antibiotic therapy can be complex and are outside the scope of this supplement.

Diagnosis of a skin abscess is the first step in a successful procedure. The majority of skin abscesses are reported to be tender and fluctuant or erythematous with induration.<sup>3</sup> Physical examination of the affected area may allow diagnosis of an underlying abscess on the basis of swelling, pain, redness, and fluctuance, when these findings are present. Spontaneously draining skin abscesses are also amenable to diagnosis by physical examination alone. Needle aspiration of a suspected skin abscess can facilitate the diagnosis of a localized abscess when physical examination is equivocal.<sup>6</sup> Bedside ultrasonography is a valuable adjunctive tool to identify localized areas of fluid under the skin that may represent an isolated area of infection; ultrasonography can also be used to measure the dimensions of the abscess.<sup>7</sup> Use of ultrasonography for this purpose is increasing and can be helpful for diagnosis. Once the diagnosis of an abscess is made, the next step is to determine whether incision and drainage are necessary. Most cutaneous abscesses are appropriate for incision and drainage when they are larger than 5 mm in diameter and are in an accessible location.

**CONTRAINDICATIONS**

Extremely large abscesses or deep abscesses in areas that are difficult to anesthetize may be treated more appropriately in a formal operating room. Incision and drainage are not indicated for cutaneous cellulitis without an underlying abscess.<sup>6</sup> The transient bacteremia associated with incision and drainage may require preoperative treatment with antibiotics and reconsideration of the timing of the procedure for patients at increased risk for endocarditis, such as those with abnormal or artificial heart valves.<sup>8</sup> Advice from an appropriate specialist may be important for abscesses involving areas of the body for which there are specific cosmetic concerns, such as the face or breast. Abscesses of the palms, soles, or nasolabial folds can be associated with complications and may require consultation with an appropriate surgical specialist.

**EQUIPMENT**

Universal precautions for potential exposure to bodily fluids should always be followed. You will need a gown, gloves, and a face mask with shield. Although strict sterile technique may not always be necessary for incision of an already infected skin site, in this era of antibiotic resistance it is reasonable to use sterile procedures for abscess drainage whenever possible. Materials needed for the incision and drainage of an abscess are similar to those needed for a laceration repair. A preassembled laceration kit should include many of the necessary items.

For preparation and anesthesia, obtain a skin-cleansing agent, sterile gauze, local anesthetic, a 5-to-10-ml syringe, and a 25-gauge or 30-gauge needle. One percent lidocaine is an appropriate anesthetic for this procedure. Lidocaine with epinephrine offers advantages such as reduced bleeding and extended duration of action. Anesthetics with epinephrine are contraindicated in areas with a single blood supply, and their use in these areas is typically avoided. Bupivacaine is another option that offers an increased duration of action.

Items necessary for incision and drainage include a scalpel blade (number 11 or 15) with handle, a small curved hemostat, normal saline with a sterile bowl, and a large syringe with a splash guard or a needleless 18-gauge angiocatheter for irrigation of the wound. Swabs for bacterial culture, wound-packing material, scissors, gauze, and tape should be available to complete the procedure and dress the wound.

**PREPARATION**

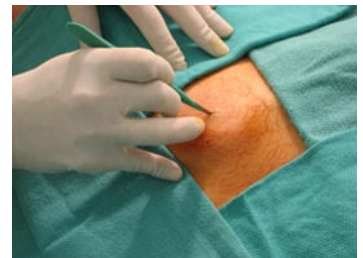Obtain informed consent after discussing the procedure and its risks and benefits with the patient. Be sure to discuss the possibilities of pain, bleeding, and scar formation with patients before obtaining consent. Take time to verify that you are treating the correct patient, to identify the correct surgical site, to obtain agreement on the procedure to be performed, and to ensure availability of all necessary equipment. Wash your hands with antibacterial soap and water before beginning the procedure. Because many abscesses are under pressure, make sure you wear gloves and a face shield at all times during the procedure to avoid exposure to bodily fluids.

Place all equipment within reach, on a bedside table. Position the patient so that the area for drainage is fully exposed and easily accessible, while ensuring the patient's comfort. Adjust the lighting to allow easy visualization of the abscess. Apply a skin cleanser, such as chlorhexidine or povidone iodine, in a circular motion, starting at the peak of the abscess. Cover a wide area outside the wound to prevent contamination of equipment.

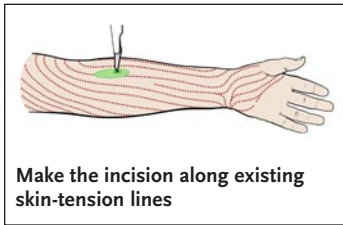
Anesthetize the top of the wound by inserting a 25-gauge or 30-gauge needle just under and parallel to the surface of the skin. Inject anesthetic into the intradermal tissues. Once the entire open bore of the needle is under the skin, use gentle pressure to infiltrate the skin with the anesthetic agent. You will note blanching of the tissue as the anesthetic spreads out. Continue with infiltration until you have covered an area over the top of the abscess large enough to anesthetize the area of incision. For some abscesses, additional injections of anesthetic in a local field block pattern,<sup>6</sup> parenteral analgesic agents, or procedural sedation may be required for the patient's comfort.

**ABSCESS INCISION AND DRAINAGE PROCEDURE**

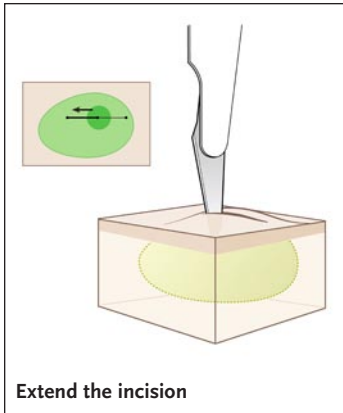
Hold the scalpel between the thumb and forefinger to make initial entry directly into the abscess. Make an incision directly over the center of the cutaneous abscess; the incision should be oriented along the long axis of the fluid collection. You may feel resistance as the incision is initiated. Steady, firm pressure will allow a controlled entry into the subcutaneous tissues. Purulent drainage will begin when the abscess



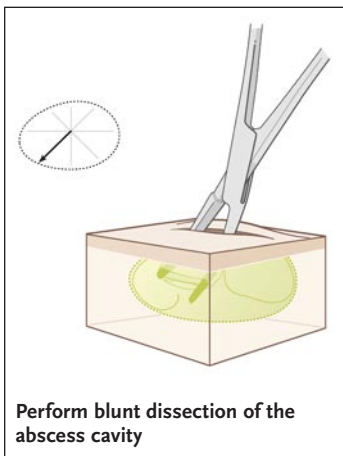
Incise directly over the center of the cutaneous abscess



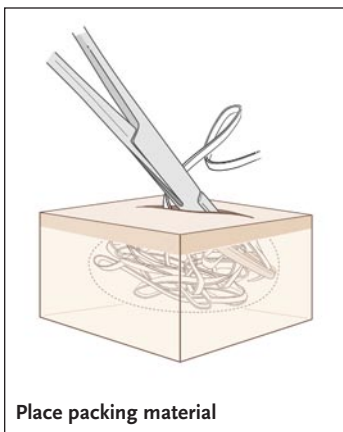
Make the incision along existing skin-tension lines



Extend the incision



Perform blunt dissection of the abscess cavity



Place packing material

cavity has been entered successfully. Control the scalpel carefully during the stab incision to prevent puncturing through the back wall, which can lead to bleeding that is difficult to control.<sup>9</sup> Cosmetic results can be optimized if the incision is made parallel to existing skin-tension lines.<sup>6,9</sup>

Extend the incision to create an opening large enough to ensure adequate drainage and to prevent recurrent abscess formation; the incision may need to extend the length of the abscess borders. The goal is to allow enough access for introduction of hemostats to break up loculations and for placement of internal packing material. If aerobic and possibly anaerobic bacterial culture are necessary, use a swab or syringe to obtain a sample from the interior aspect of the abscess cavity. Although most patients will not require antibiotics after successful incision and drainage,<sup>1-5</sup> a culture can be very useful during a follow-up appointment, especially if the abscess has clinically worsened and treatment with antibiotics becomes necessary.

After allowing the wound to drain spontaneously, gently express any further contents. If the patient is experiencing significant discomfort, additional injections of local anesthetic may be helpful. Use curved hemostats for further blunt dissection to break loculations and to allow the abscess cavity to be opened completely. Insert a curved hemostat into the wound until you feel the resistance of healthy tissue, then open the hemostat to perform blunt dissection of the internal portion of the abscess cavity. Continue to break up loculations in a circular motion until the entire abscess cavity has been explored. Identify any deep tracts that extend into surrounding tissues. Gently irrigate the wound with normal saline, using a syringe with splash shield or a needleless, 18-gauge angiocatheter, to reach the interior of the abscess cavity. An appropriate incision size will enhance irrigation and prevent excessive buildup of pressure within the abscess cavity. Continue irrigation until the effluent is clear.

Using wound-packing material, such as 1/4- or 1/2-in. packing strips with or without iodoform, gently pack the abscess by starting in one quadrant and gradually working around the entire cavity. Place sufficient packing material to keep the walls of the abscess separated and to allow further drainage of infected debris. This will allow healing by secondary intention and prevent premature closure of the wound, which can lead to re-accumulation of bacteria and recurrent abscesses. Avoid overpacking the wound; this may cause ischemia of the surrounding tissues and can impede the desired drainage of purulent material.

#### AFTERCARE

Subsequent treatment with antibiotics is not required after most successful incision and drainage procedures performed in healthy patients.<sup>1-5</sup> For a simple abscess, the openly draining wound allows the body's host defenses to clear the infection without the need to expose patients to the potential adverse effects of antimicrobial therapy. Patients with extensive cellulitis beyond the abscess area or with significant comorbidities may require supplemental treatment with antibiotics. Providers are encouraged to use local bacterial-culture susceptibility data to guide any such empiric therapy.

Community-acquired methicillin-resistant *Staphylococcus aureus* (MRSA) has garnered heightened attention with the increasing awareness of cutaneous abscess involvement. Knowing and following your regional management guidelines is imperative. Some communities have reported up to a 74% incidence of this pathogen in cutaneous abscesses,<sup>10,11</sup> although there is no evidence to suggest that abscesses caused by community-acquired MRSA are more likely to require empiric antibiotic therapy.

Cover the abscess wound with a sterile, nonadherent dressing. Topical antibiotics

have a limited benefit and are not required. Check that the patient's tetanus immunizations are up-to-date. Remove packing material from all abscesses within a few days; schedule a follow-up appointment for 2 or 3 days after the procedure, to remove packing material from the wound. Patients should expect some continued drainage from the packed wound. Instruct the patient to return before the scheduled appointment if there are any signs of worsening, including redness, swelling, or development of systemic symptoms such as fever.

On subsequent visits for wound care, remove any packing material to allow assessment of healing by secondary intention. If substantial wound drainage has continued, use fresh packing material to continue the healing process, and schedule an additional follow-up visit for 2 to 3 days later. Continued drainage is common for abscesses that required extensive initial drainage and in the absence of other signs of worsening infection is not itself an indication for treatment with antibiotics.

#### COMPLICATIONS

The acidic environment of infected tissue can lead to difficulties with providing sufficient anesthesia with local agents. Using appropriate amounts of anesthetic, allowing sufficient time after injection, or supplementing with oral or parenteral agents can increase the patient's comfort. Progression to surrounding cellulitis or lymphangitis, development of fever, or other signs of clinical worsening may mean that repeat incision and drainage or antibiotic treatment should be considered. If an abscess recurs despite adequate drainage, further investigation may be warranted to rule out underlying risk factors or abnormalities such as staphylococcal colonization or anatomic, immunologic, or infectious disorders. Most abscesses respond well to simple incision and drainage and do not require treatment beyond the changing of packing material and the application of local wound care.

No potential conflict of interest relevant to this article was reported.

#### REFERENCES

1. Meislin HW, Lerner SA, Graves MH, et al. Cutaneous abscesses: anaerobic and aerobic bacteriology and outpatient management. *Ann Intern Med* 1977;87:145-9.
2. Rutherford WH, Hart D, Calderwood JW, Merrett JD. Antibiotics in surgical treatment of septic lesions. *Lancet* 1970;1:1077-80.
3. Llera JL, Levy RC, Staneck JL. Cutaneous abscesses: natural history and management in an outpatient facility. *J Emerg Med* 1984;1:489-93.
4. Llera JL, Levy RC. Treatment of cutaneous abscess: a double-blind clinical study. *Ann Emerg Med* 1985;14:15-9.
5. Hankin A, Everett WW. Are antibiotics necessary after incision and drainage of a cutaneous abscess? *Ann Emerg Med* 2007;50:49-51.
6. Halvorson GD, Halvorson JE, Iserson KV. Abscess incision and drainage in the emergency department — part I. *J Emerg Med* 1985;3:227-32.
7. Squire BT, Fox JC, Anderson C. ABSCESS: applied bedside sonography for convenient evaluation of superficial soft tissue infections. *Acad Emerg Med* 2005;12:601-6.
8. Fine BC, Sheckman PR, Bartlett JC. Incision and drainage of soft-tissue abscesses and bacteremia. *Ann Intern Med* 1985;103:645.
9. Burney RE. Incision and drainage procedures: soft tissue abscesses in the emergency service. *Emerg Med Clin North Am* 1986;4:527-42.
10. Frazee BW, Lynn J, Charlebois ED, Lambert L, Lowery D, Perdreau-Remington F. High prevalence of methicillin-resistant *Staphylococcus aureus* in emergency department skin and soft tissue infections. *Ann Emerg Med* 2005;45:311-20.
11. Moran GJ, Krishnadasan A, Gorwitz RJ, et al. Methicillin-resistant *S. aureus* infections among patients in the emergency department. *N Engl J Med* 2006;355:666-74.

Copyright © 2007 Massachusetts Medical Society.