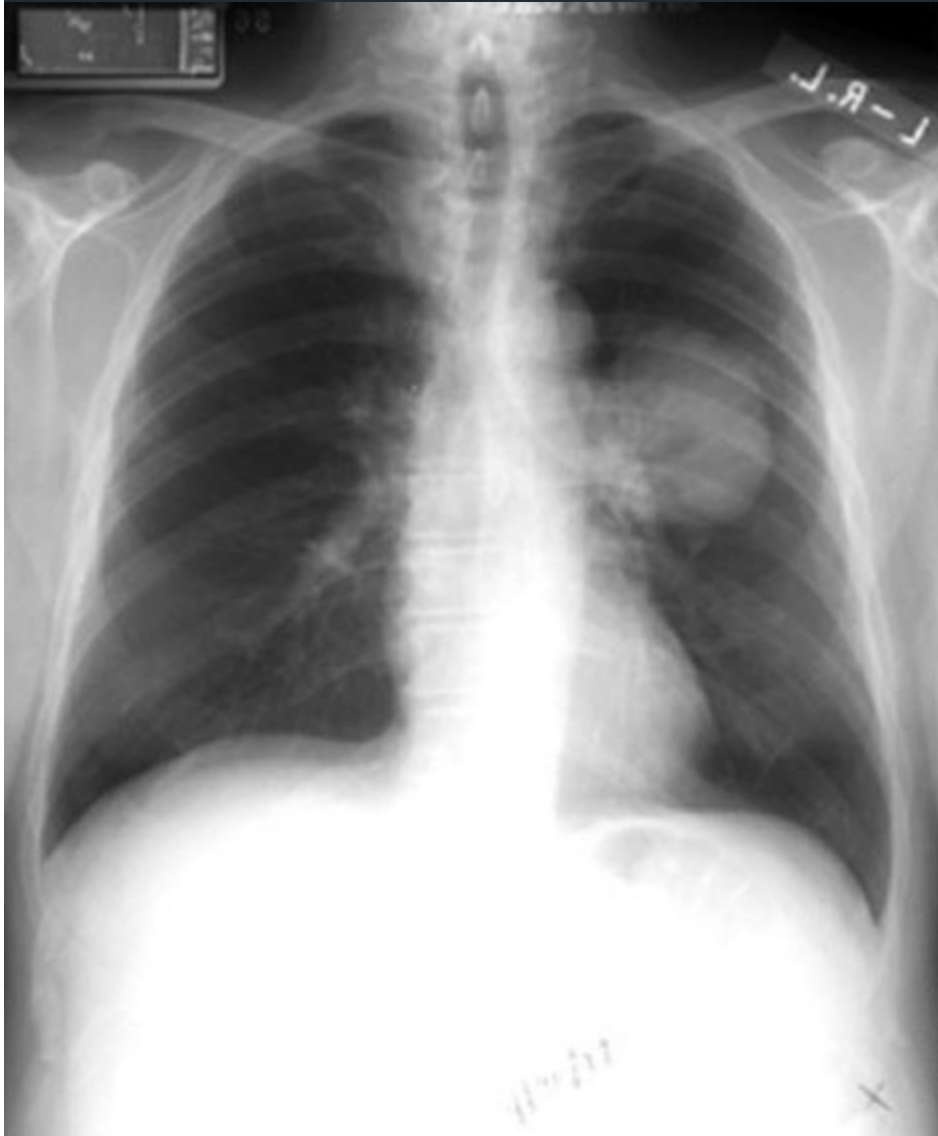



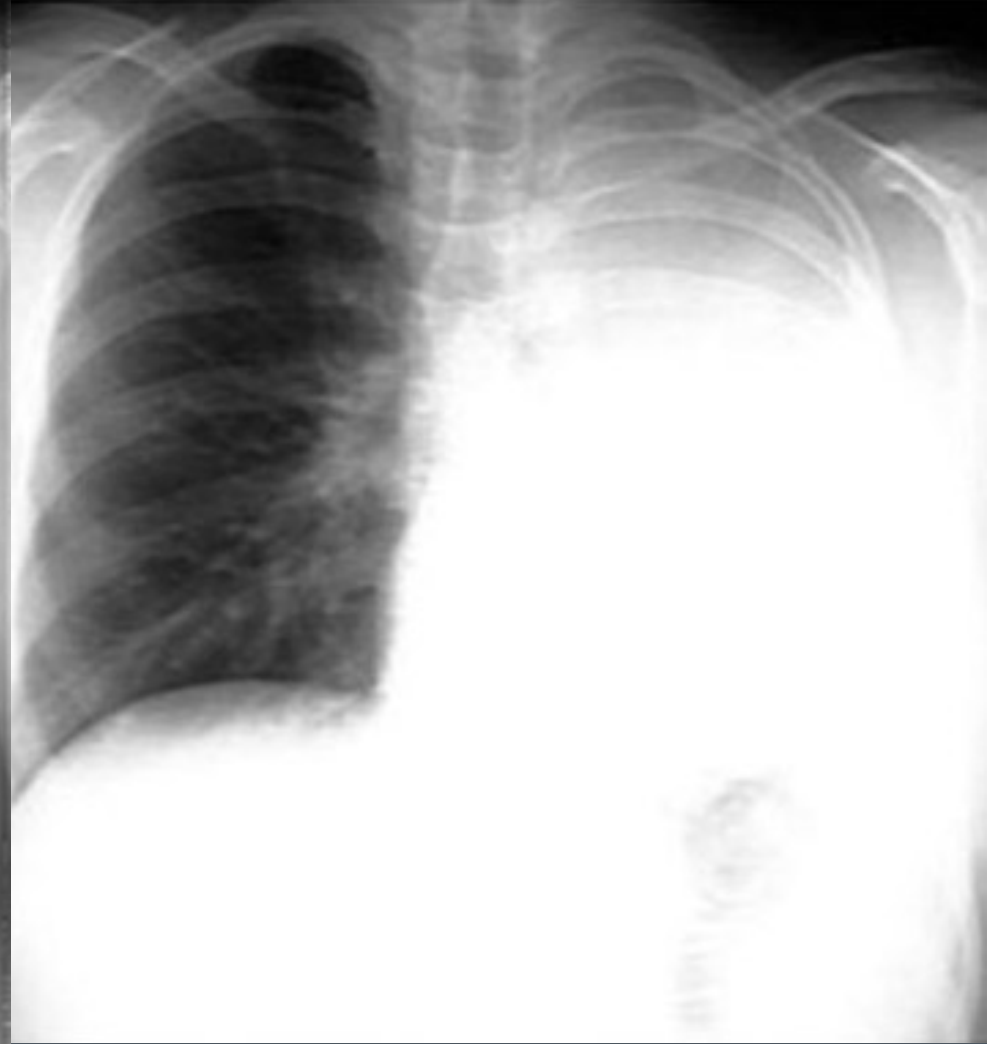
# Massive Hemoptysis

Emergent management in the hospitalized patient

Admission 12/9/2010



Morning 12/10/2010 when hypoxic





# Definition

- 100 to 600 mL expectorated blood over a 24-hour period



# Etiologies

- Malignancy – Bronchogenic carcinoma
- Tuberculosis
- Bronchiectasis
- Invasive fungal infections
- Severe pulmonary HTN
- Hardware erosion

# Acute Management

- Airway protection
  - Large ET tube (size 8.0 or greater)
  - Place bleeding lung in a dependent position
  - Selective Right mainstem intubation
    - Right upper lobe bronchus blocked
  - CVSurgical/IR involvement quickly
    - Angiogram/embolization
    - Double-lumen ET tube
    - 4 Fr 100 cm Fogarty balloon catheter
- Reverse Coagulopathies
- CV support – type/cross/transfuse products

